

# Pre-excited atrial fibrillation in pregnant woman: A Case Report

## Fibrillation atriale pré-excitée chez une femme enceinte : A propos d'un cas

Mariam Jabeur, Rania Gargouri, Amine Bahloul, Tarek Ellouze, Faten Triki, Selma Charfeddine, Leila Abid.  
*Department of Cardiology, Hedi Chaker University Hospital of SFAX*

### RÉSUMÉ

La grossesse est associée à une incidence accrue des arythmies cardiaques, probablement en raison de changements hormonaux, hémodynamiques et du système nerveux autonome. Cependant, il existe peu de données concernant l'efficacité et la sécurité des antiarythmiques pour traiter et prévenir la fibrillation atriale pré-excitée chez les femmes enceintes.

Nous rapportons le cas d'une femme enceinte qui a présenté une fibrillation atriale pré-excitée comme première manifestation d'un syndrome de Wolff–Parkinson–White. Elle a été traitée avec de la flécaïnide, sans récurrence des arythmies ni événements indésirables liés au traitement.

### MOTS-CLÉS

Syndrome de Wolff–Parkinson–White  
• Flécaïnide •  
Fibrillation atriale pré-excitée

### SUMMARY

Pregnancy is associated with an increased incidence of cardiac arrhythmias likely due to hormonal, haemodynamic and autonomic changes. Yet, there is little data available regarding the efficacy and safety of anti-arrhythmic agents to treat and prevent pre-excited atrial fibrillation (AF) in pregnant women.

We report a case of pregnant woman who developed pre-excited AF as the first manifestation of Wolff–Parkinson–White syndrome. She was treated with flecainide with neither arrhythmias recurrence nor adverse events of the treatment.

### KEYWORDS

Wolff–Parkinson–White syndrome  
• Flecainide •  
Pre-excited atrial fibrillation

### Correspondance

Mariam Jabeur, MD  
Department of Cardiology  
Hedi Chaker University Hospital, Sfax  
Email: mariemjabeur2@gmail.com

## INTRODUCTION

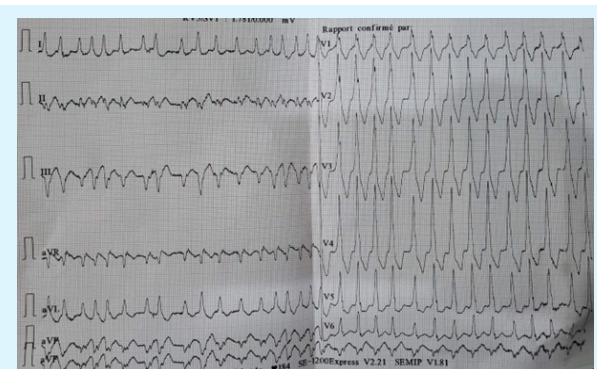
Pregnancy is associated with an increased incidence of cardiac arrhythmias likely due to hormonal, haemodynamic, and autonomic changes.<sup>(1)</sup> Arrhythmias generally occur with pre-existing symptoms but can also manifest for the first time during pregnancy. (2) Supraventricular tachycardias (SVT) are the most common cause of cardiac arrhythmias in pregnant women and their clinical course is generally benign. However, because blood pressure during SVT is lower than normal, SVT can lead to fetal adverse events including respiratory distress, small fetus for gestational age, and prematurity. Because atrial fibrillation (AF) can be transmitted rapidly to the ventricle through an accessory pathway, life-threatening malignant ventricular arrhythmias affecting both the fetus and the pregnant woman may occur.

Pre-excited atrial fibrillation (AF) in a pregnant woman is a rare but potentially serious condition that requires careful management to ensure the safety of both the mother and the fetus. The management of pre-excited AF in pregnant women is often difficult and challenging.

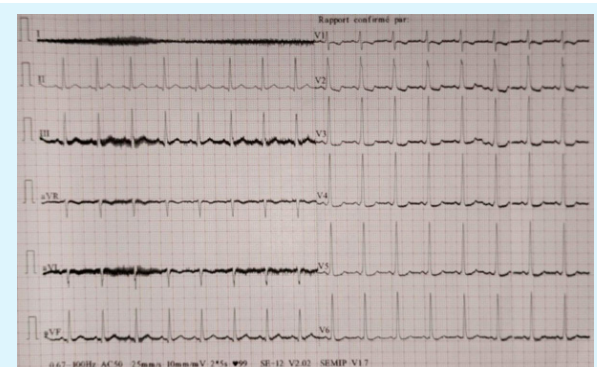Here, we report a case in which pregnant woman developed AF rapidly conducted to the ventricle through an overt accessory pathway as the first manifestation of Wolff–Parkinson–White (WPW) syndrome and were successfully treated with flecainide.

## CASE REPORT

A 40-year-old pregnant (27 weeks of gestation) multipara (4th pregnancy) woman was admitted to the intensive care unit for palpitations and presyncope. At admission, physical examination showed irregular tachycardia with normal blood pressure (100/65 mmHg) and no evidence of respiratory failure. The Electrocardiogram (ECG) showed irregular wide QRS complex tachycardia with right bundle branch morphology suggestive of AF conducted to the ventricles (Figure 1). Oral loading single dose of flecainide (300 mg) effectively restored sinus rhythm and ECG demonstrated a left-sided accessory pathway (Figure 2). Transthoracic echocardiography was unremarkable.



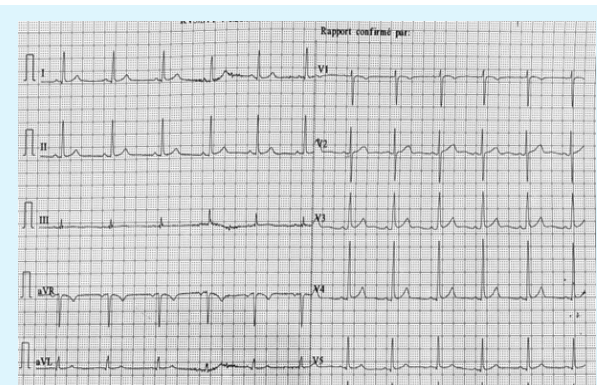
**Figure 1.** Electrocardiogram on admission was suggestive of pre-excited AF. Minimum pre-excited RR interval was 200 ms



**Figure 2.** Electrocardiogram after termination of atrial fibrillation episode with oral loading single dose of flecainide (300 mg) revealed the presence of a left-sided accessory pathway

Blood samples showed normal thyroid-stimulating hormone (TSH) levels. Oral flecainide at a daily dose of 150 mg (prolonged-release capsules) was started and maintained at this dose until delivery.

ECG showed the disappearance of the pre-excitation pattern and the patient remained free of symptoms during follow-up (Figure 3).



**Figure 3.** Electrocardiogram during follow-up and while the patient was taking oral flecainide showed the disappearance of the pre-excitation

Monthly fetal monitoring revealed normal growth. Cesarean delivery occurred at 37 Weeks of gestation with no maternal or fetal complications.

An electrophysiologic study was performed 3 months after delivery and demonstrated the presence of a postero-lateral accessory pathway with an anterograde effective refractory period measured at 230ms. Ablation of the accessory pathway was performed with immediate success. She had no further events or complications. She had no recurrence during one-year follow-up.

## DISCUSSION

In this case of pregnant woman, we found that:

- Oral loading single dose of flecainide (300mg) is effective in cardioversion of pre-excited atrial fibrillation.

- Flecainide was effective to prevent WPW-associated malignant arrhythmias without any fetal complications.

Pregnancy is associated with an increased risk of SVT that can potentially lead to adverse maternal and/or foetal outcomes. Atrioventricular nodal re-entrant tachycardia and orthodromic atrioventricular

re-entrant tachycardia associated with WPW syndromes are the two most frequent causes of SVT in pregnant women. Manifest accessory pathways occur in 0.1–0.3% of the general population and

symptoms related to WPW syndrome are generally linked to atrioventricular reentrant tachycardia (AVRT). Rarely anterograde conduction through an accessory pathway can occur during AF with the potential of degenerating into ventricular fibrillation (VF) if conduction is particularly rapid. In the presence of an accessory pathway with anterograde conduction it is estimated that the 10-year risk of sudden cardiac death ranges between 0% and 0.15%.<sup>(3)</sup> Previous history of symptomatic tachycardia, young age, multiple accessory pathways, refractory periods of the accessory pathway <240 ms, and shortest pre-excited RR intervals <250ms have been associated with an increased risk of malignant arrhythmias.

The management of pre-excited AF is often challenging for many reasons:

**Maternal hemodynamics:** Rapid ventricular response can compromise cardiac output and lead to maternal instability.

**Fetal health:** Maternal hypotension, hypoxia, or tachyarrhythmia can reduce uteroplacental blood flow, endangering the fetus.

**Drug safety:** Medications commonly used to treat arrhythmias may pose risks to the developing fetus, so the choice of treatment must balance maternal and fetal safety.

Flecainide acetate is a sodium channel-blocking drug that decreases the rate of rise of phase 0 but has little effect on the duration of the action potential.

Flecainide prolongs the effective refractory period of the right atrium, the right ventricle, and the atrio-ventricular node and has greater electrophysiological effects on accessory pathways<sup>(4)</sup>. Neuss et al.<sup>(5)</sup> investigated the electrophysiological effects of flecainide on accessory pathways in 12 patients with WPW syndrome. Intravenous administration of 100mg flecainide increased the ventriculo-atrial block by an average of 130 ms in 10 of 11 patients with retrograde conduction through the accessory pathway. They also found that intravenous administration of 100mg flecainide resulted in a complete block of the accessory pathway in sinus rhythm in 7/12 patients, as occurred in Patient 2 in our series. Additionally, rapid atrial pacing induced AF with rapid ventricular response in five patients, and flecainide slowed ventricular response in three and complete block of the accessory pathway in two of these patients, as occurred in Patient 1 in our series. Kappenberger and al.<sup>(6)</sup> reported similar findings in nine patients with severe WPW syndrome, in which 2mg/kg flecainide increased shortest ventricular responses during pre-excited AF from 218 to 320 ms and converted AF to sinus rhythm in four patients. The usefulness of flecainide in treating patients at risk of malignant arrhythmias is further supported by its ability to prevent AF recurrence.<sup>(7)</sup>

S. Chauveau and al<sup>(4)</sup> described three cases of pregnant women who developed AF rapidly conducted to the ventricle through an overt accessory pathway as the first manifestation of Wolff–Parkinson–White syndrome and demonstrated that the use of flecainide is a reasonable therapeutic option for the treatment of WPW-associated malignant arrhythmias in pregnant women.

Flecainide exhibits properties capable of preventing malignant arrhythmias by both preventing AF or AVRT-induced AF, and increasing the RR interval of pre-excited AF. The use of flecainide in pregnant women appears safe, as it has not been associated with malformative syndromes and is currently used to treat severe fetal arrhythmias.(8)

Catheter-based approaches have been proven effective for the prevention of tachycardias associated with WPW. However, performing accessory pathway ablation in pregnant women exposes the fetus and the women to potentially harmful radiation and side effects of the ablation technique (article flecainide). Zero-fluoroscopy catheter ablation for severe arrhythmia in pregnant women is possible and has been reported in a single case in a small series, but this technology still exposes the patient and the fetus to vascular access, catheter manipulation, and the delivery of radiofrequency energy with an incidence of complications as high as 3%. (9,10–11) Physicians should also be aware that the failure rate of accessory pathway ablation ranges between 5% and 7% and may be delayed after apparent immediate success.(9)

## CONCLUSION

This case supports the use of flecainide as a reasonable therapeutic option for the treatment of WPW-associated malignant arrhythmias in pregnant women whether in cardioversion or in prevention of WPW-associated malignant arrhythmias without any maternal or fetal complications.

## REFERENCES

1. Enriquez AD, Economy KE, Tedrow UB. Contemporary management of arrhythmias during pregnancy. *Circ Arrhythm Electrophysiol* 2014;7:961–967.
2. Lee SH, Chen SA, Wu TJ, Chiang CE, Cheng CC, Tai CT, Chiou CW, Ueng KC, Chang MS. Effects of pregnancy on first onset and symptoms of paroxysmal supraventricular tachycardia. *Am J Cardiol* 1995;76:675–678. SM. 2015 ACC/AHA/HRS guideline for the management of adult patients with supraventricular tachycardia: a report of the American College of Cardiology/American Heart Association Task Force on Clinical Practice Guidelines and the Heart Rhythm Society. *J Am Coll Cardiol* 2016;67:e27–115.
3. Pediatric and Congenital Electrophysiology Society (PACES); Heart Rhythm Society (HRS); American College of Cardiology Foundation (ACCF); American Heart Association (AHA); American Academy of Pediatrics (AAP); Canadian Heart Rhythm Society (CHRS), Cohen MI, Triedman JK, Cannon BC, Davis AM, Drago F, Janousek J, Klein GJ, Law IH, Morady FJ, Paul T, Perry JC, Sanatani S, Tanel RE. PACES/HRS expert consensus statement on the management of the asymptomatic young patient with a Wolff-Parkinson-White (WPW, ventricular preexcitation) electrocardiographic pattern: developed in partnership between the Pediatric and Congenital Electrophysiology Society (PACES) and the Heart Rhythm Society (HRS). Endorsed by the governing bodies of PACES, HRS, the American College of Cardiology Foundation (ACCF), the American Heart Association (AHA), the American Academy of Pediatrics (AAP), and the Canadian Heart Rhythm Society (CHRS). *Heart Rhythm* 2012;9:1006–1024.
4. Samuel Chauveau I,2, Olivier Le Vasseur3, Elodie Morel 2, Arnaud Dulac I, and Philippe Chevalier. Flecainide is a safe and effective treatment for pre-excited atrial fibrillation rapidly conducted to the ventricle in pregnant women: a case series. *European Heart Journal - Case Reports* (2019) 3, 1–7.
5. Neuss H, Buss J, Schlepper M, Berthold R, Mitrovi cV, Kra¨mer A, Musial WJ. Effects of flecainide on electrophysiological properties of accessory pathways in the Wolff-Parkinson-White syndrome. *Eur Heart J* 1983;4:347–353.
6. Kappenberger LJ, Fromer MA, Shenasa M, Gloor HO. Evaluation of flecainide acetate in rapid atrial fibrillation complicating Wolff-Parkinson-White syndrome. *Clin Cardiol* 1985;8:321–326.
7. Aliot E, Capucci A, Crijns HJ, Goette A, Tamargo J. Twenty-five years in the making: flecainide is safe and effective for the management of atrial fibrillation. *Europace* 2011;13:161–173.
8. Vigneswaran TV, Callaghan N, Andrews RE, Miller O, Rosenthal E, Sharland GK, Simpson JM. Correlation of maternal flecainide concentrations and therapeutic effect in fetal supraventricular tachycardia. *Heart Rhythm* 2014;11:2047–2053.
9. Page RL, Joglar JA, Caldwell MA, Calkins H, Conti JB, Deal BJ, Estes NAM, Field ME, Goldberger ZD, Hammill SC, Indik JH, Lindsay BD, Olshansky B, Russo AM, Shen WK, Tracy CM, Al-Khatib Manjaly Z-R, Sachdev B, Webb T, Rajappan

- K. Ablation of arrhythmia in pregnancy can be done safely when necessary. *Eur J Obstet Gynecol Reprod Biol* 2011; 157:116–117.
10. Szumowski L, Szufladowicz E, Orczykowski M, Bodalski R, Derejko P, Przybylski A, Urbanek P, Ku smierczyk M, Ko zluk E, Sacher F, Sanders P, Dangel J, Haissaguerre M, Walczak F. Ablation of severe drug-resistant tachyarrhythmia during pregnancy. *J Cardiovasc Electrophysiol* 2010;21:877–882.
11. Tak T, Berkseth L, Malzer R. A case of supraventricular tachycardia associated with Wolff-Parkinson-White syndrome and pregnancy. *WMJ* 2012;111:228–232.