

# Primary Pulmonary Vein Stenosis (PPVS): a case report

Elleuch Amal<sup>1</sup>, Loukil Mouna<sup>1</sup>, Gargouri Rania<sup>2</sup>, Feki Manel<sup>1</sup>, Abid Leila<sup>2</sup>, Safi Faiza<sup>1</sup>

1- Department of Pediatric Emergency and Reanimation, Hedi Chaker Hospital, Sfax, Tunisia

2- Department of Cardiology; University Hospital Habib Bourguiba Sfax, Tunisia; Sfax University

## ABSTRACT

Primary Pulmonary vein stenosis (PPVS) in the pediatric population is a rare disorder linked with conditions such as bronchopulmonary dysplasia, prematurity, congenital heart disease. It leads to pulmonary hypertension, right ventricular failure, and mortality in approximately 50% of the cases. Pathophysiology of this condition is still poorly understood. Risk factors for mortality include younger age at diagnosis, greater number of affected veins, bilateral pulmonary vein involvement and right ventricular dysfunction. Physicians have used many approaches to relieve obstructions resulting from PPVS. Both surgical and transcatheter therapies have been successful in offering transient relief, but with poor mid- and long-term outcomes.

## KEYWORDS

Primary pulmonary vein stenosis, pulmonary hypertension, cardiac catheterization

## SUMMARY

Primary pulmonary vein stenosis is a rare disease that involves obstruction of the large pulmonary veins and blood flow from the lungs to the left atrium leading to high pulmonary venous pressure and hypoxemia.(1) Pathophysiology of this condition is still misunderstood. Recent research suggests that PPVS is an evolving problem in newborns.(2)

## MOTS-CLÉS

Pericardial effusion, Tamponade, Diagnosis, Echocardiography, Drainage, Etiology

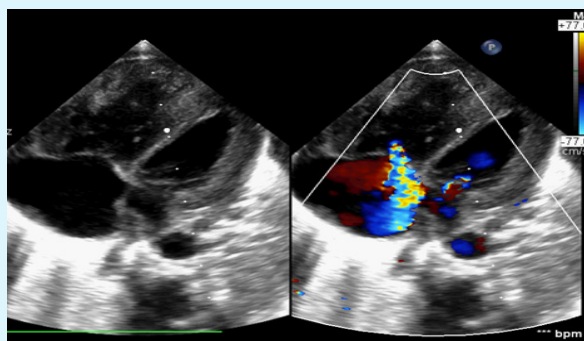
## Correspondance

A Elleuch

Department of Pediatric Emergency and Reanimation, Hedi Chaker Hospital, Sfax, Tunisia, Department of Cardiology; University Hospital Habib Bourguiba Sfax, Tunisia; Sfax University

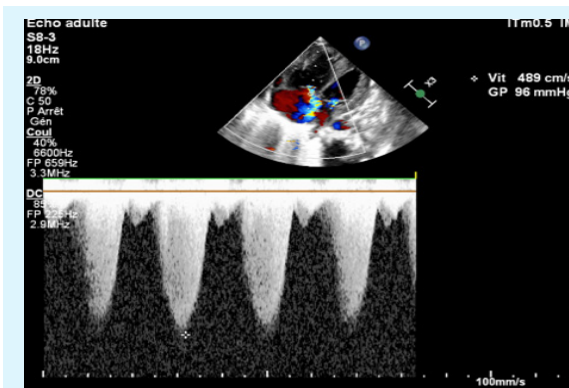
## CASE STUDY

The patient, an ex-full term 6 days old child, admitted to the pediatric intensive care unit for shortness of breath. The family history includes distant consanguinity and no heart disease. The two brothers and a sister are in good health. She had been tachypneic since birth and had gained little weight since her discharge from the hospital. The patient was afebrile with a respiratory rate of 75 breaths/ min, oxygen saturation 73% in the ambient air. There was a grade 4/6 systolic murmur heard throughout the precordium. Her liver was palpable 3 cm below the right costal margin. A chest radiograph revealed cardiomegaly with a large right atrium, prominent pulmonary vessels and bilateral interstitial thickening. Cardiac ultrasound initial evaluation had suspected abnormal total supra cardiac pulmonary venous return with a retro left auricle collector which receives the 4 Pulmonary Veins, flows into a vertical vein to join the superior vena cava. Very dilated right cavities and pulmonary hypertension (PH) measured at 65mmHg were identified. There was an atrial septal defect and right-left canal arterial shunt. There was no shunt at the ventricular level and the arch was free. Thoracic angio-CT revealed short stenosis at the junction of the upper and lower left pulmonary veins, which were decreased in caliber measuring 1.3mm and 2mm respectively, complicated by PH (figures 1-4). Diuretic therapy associated to pulmonary arterial antihypertension medication (sildenafil) was initiated. The outcome was marked by persistent dyspnea and failure of oxygen weaning with persistent signs of right ventricular failure despite medical treatment optimization.

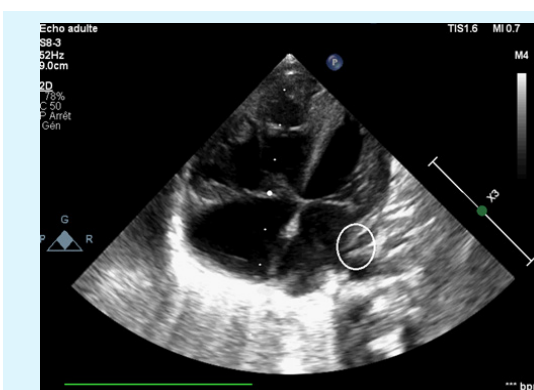


**Figure 1.** Dilatation des cavités droites avec un IT importante et petite oreillette gauche

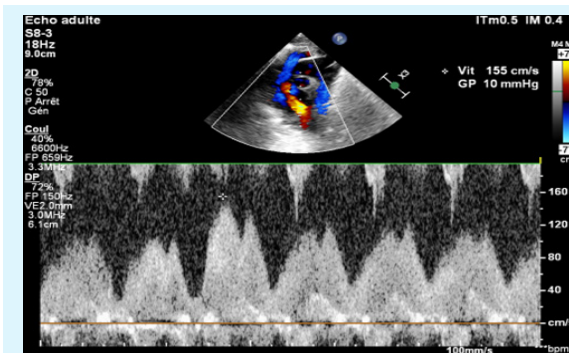
A control cardiac ultrasound realized within 5 days of hospitalization demonstrated a severely dilated right ventricle, a significant tricuspid insufficiency with a PAPS= 100mmHg (was 65) and a significant flow acceleration on the left inferior pulmonary vein with max Speed= 1.49m/s. Due to the rapidly progressive stenosis despite treatment, the child was deemed not a surgical candidate and was transferred to palliative care. The infant deteriorated rapidly and died within a few days.



**Figure 2.** Estimation de la PAPS 96 mmhg sur le flux d el IT



**Figure 3.** Striction à l'abouchement de la VP inférieure gauche dans l'oreillette gauche



**Figure 34** Accélération du flux veineux pulmonaire au doppler pulsé à 155 cm/s

## DISCUSSION

PPVS is an idiopathic disorder related to mesenchymal proliferation that leads to changes in pulmonary venous vasculature, commonly associated with chronic lung disease.(3) Infants with PPVS are at a high risk of morbidity and mortality, especially in the first two years of life.(3) As in the present case, about half of pediatric patients with primary PPVS have an associated heart defect. Primary PPVS has also been reported to be associated with bronchopulmonary dysplasia and pre-term births.(1,4) Growth retardation, increased dyspnea, usually lead infants with PPVS to seek medical attention.(5) Chest X-ray commonly reveals interstitial and reticular opacities resulting from venous congestion and fluid in the alveolar space.(6) Transthoracic echocardiography with pulsed doppler allows in most cases a basic evaluation and is useful for follow-up. The diagnosis of PPVS is made on the basis of pulsed and continuous wave doppler profiles showing turbulent, continuous, nonphasic, or monophasic flow. Mean gradients exceeding 2 m/s or the lack of flow reversal at end-diastole in the presence of a nonphasic pulsed doppler profile are assumed to represent pulmonary vein stenosis.(4) In a systematic review, the most frequent reported location of stenosis at diagnosis was left upper pulmonary vein (53.5%). Bilateral vein stenoses at presentation were seen in 51.9% of reported cases. (2) Cardiac computerized tomography CT is valuable for the initial PPVS diagnosis, for procedure planning, and for monitoring the disease progression. It provides excellent morphological information anatomic detail to identify the number of affected vessels and characterize the degree of damage in each vessel.(7) The treatment consists of catheter dilatations of the pulmonary veins with or without stenting, surgical interventions, medical treatment, and, in rare cases, lung transplantation. Various surgical strategies have been used. (8–10) Sutureless repair is currently the most commonly used, but venoplasty, endarterectomy, ostial resection, and reimplantation are also used in some circumstances. Medical therapies such as vinblastine, methotrexate, imatinib and bevacizumab are increasingly being used in an attempt to suppress the myofibroblastic proliferation seen in patients with PPVS. (8) Adjuvant therapies such as pulmonary arterial antihypertensives (eg, sildenafil) are used off-label to

enhance right ventricular function.(11) For refractory end-stage PPVS, lung transplantation has been used as an alternative treatment strategy. However, despite the various innovative approaches used, morbidity and mortality are still high.

## CONCLUSION

PPVS is a rare and understudied disease with a significant mortality rate. Further investigation of risk factors for mortality and best management practices would provide an opportunity for countries with limited resources to stratify risk and offer treatment to the patients with the best chance of survival.

## REFERENCES

1. Latson LA, Prieto LR. Congenital and Acquired Pulmonary Vein Stenosis. *Circulation*. 2 janv 2007;115(1):103-8.
2. Backes CH, Nealon E, Armstrong AK, Cua CL, Mitchell C, Krishnan U, et al. Pulmonary Vein Stenosis in Infants: A Systematic Review, Meta-Analysis, and Meta-Regression. *J Pediatr*. juill 2018;198:36-45.e3.
3. DiLorenzo MP, Santo A, Rome JJ, Zhang H, Faerber JA, Mercer-Rosa L, et al. Pulmonary Vein Stenosis: Outcomes in Children With Congenital Heart Disease and Prematurity. *Semin Thorac Cardiovasc Surg*. 2019;31(2):266-73.
4. Mahgoub L, Kaddoura T, Kameny AR, Lopez Ortego P, Vanderlaan RD, Kakadekar A, et al. Pulmonary vein stenosis of ex-premature infants with pulmonary hypertension and bronchopulmonary dysplasia, epidemiology, and survival from a multicenter cohort. *Pediatr Pulmonol*. août 2017;52(8):1063-70.
5. Bini RM, Cleveland DC, Ceballos R, Bargeron Jr LM, Pacifico AD, Kirklin JW. Congenital pulmonary vein stenosis. *Am J Cardiol*. 1984;54(3):369–375.
6. Mayhew CE, Lee EY, Balasubramanian S, Muneeb M, Gauvreau K, Tracy DA, et al. Chest radiographic findings in pediatric patients with intraluminal pulmonary vein stenosis. *Congenit Heart Dis*. 2014;9(2):151–157.
7. Ou P, Marini D, Celermajer DS, Agnoletti G, Vouhé P, Sidi D, et al. Non-invasive assessment of congenital pulmonary vein stenosis in children using cardiac-non-gated CT with 64-slice technology. *Eur J Radiol*. juin 2009;70(3):595-9.
8. Kuo JA, Petit CJ. Pulmonary Vein Stenosis in Children: A Programmatic Approach Employing Primary and Anatomic Therapy. *Children*. 30 juill 2021;8(8):663.

9. Frank DB, Levy PT, Stiver CA, Boe BA, Baird CW, Callahan RM, et al. Primary pulmonary vein stenosis during infancy: state of the art review. *J Perinatol*. juill 2021;41(7):1528-39.
10. McLennan DI, Solano ECR, Handler SS, Lincoln J, Mitchell ME, Kirkpatrick EC. Pulmonary Vein Stenosis: Moving From Past Pessimism to Future Optimism. *Front Pediatr* [Internet]. 5 oct 2021 [cité 29 avr 2023];9. Disponible sur: <https://www.frontiersin.org/articles/10.3389/fped.2021.747812/full>
11. Sourla E, Paspala A, Boutou A, Kontou P, Stanopoulos I, Pitsiou G. A case of pulmonary veno-occlusive disease: diagnostic dilemmas and therapeutic challenges. *Ther Adv Respir Dis*. 2013;7(2):119–123.